

Impacted canines represent an increasingly frequent anomaly, of particular importance for the functionality of the dentomaxillary system and aesthetic appearance. The literature describes the importance of canines for mastication, static occlusal relationships, guidance of the movement of laterality, as well as aesthetic appearance which has been given special attention over the last period due to canine exposure during speech and smile. Positive diagnosis can be made following clinical, paraclinical examination, and exclusion of differential diagnoses. Examination starts with an interview during which the doctor collects data required for correct diagnosis [9-10].

Clinical examination begins with extra-oral inspection, compulsorily followed by intra-oral inspection. Frequently, extra-oral inspection does not detect signs of impaction, facial symmetry being maintained. Intra-orally, there are signs of a permanent canine embedded in the jaw bone, which at the age of about 11 years should emerge in the arch [11].

The pathognomonic sign of impaction is called Quintero's sign, which describes a vestibularized position of the upper lateral incisor crown and its mesiovestibular rotation. On palpation, an asymmetry of the alveolar process, an immobile vestibular or palatal bulge of firm consistency is detected [11].

MATERIAL AND METHOD

We conducted a study in 18 patients out of 200 patients of the Clinic of Dentofacial Orthodontics and Orthopedics Cluj-Napoca, who requested a treatment plan in the period 2014-2017. The materials used in the study were: patients' medical records, the orthopantomographic radiographs, study models and photographs of each case.

The studied parameters were: frequency of canine impaction, sex distribution, frequency of maxillary impaction, predominantly affected quadrant, type of impaction, degree of impaction in relation to the lateral incisor, state of lateral incisors in bilateral impaction, and persistence or not of a deciduous canine in the arch.

The degree of impaction on OPT was established depending on the vertical height of the canine crown in relation to the lateral incisor, while the literature describes 4 degrees of impaction.

First degree, when the canine is situated below the cementoenamel junction, 2nd degree, when the canine is found above the cementoenamel junction, at less than half of the height of the lateral incisor root, 3rd degree, when the canine is above the cementoenamel junction, at more than half of the height of the lateral incisor root, without reaching the apex, and 4th degree, when the canine is situated above the lateral incisor apex.

The data obtained following the study were compared with the literature data.

RESULTS

The frequency of canine impaction following the study was 8% (figure 1).

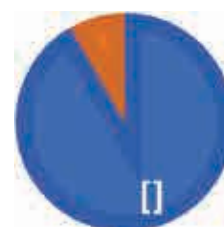

FIGURE 1. The frequency of canine impaction

Regarding the sex distribution of the number of canine impaction cases, the study showed a more frequent involvement of the male sex, with a percentage of 56% compared to the female sex, with 44% (figure 2).




FIGURE 2. Sex distribution of canine impaction

The most frequently affected arch was the maxillary arch (figure 3).

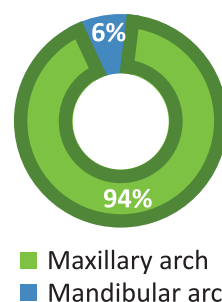


FIGURE 3. The most frequently affected arch

With respect to the affected maxillary quadrant, there were no differences between the cases where the right or the left quadrant was predominantly affected, an equal percentage being obtained for the two situations (figure 4).

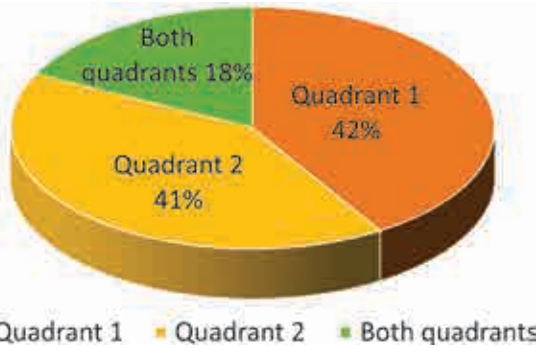


FIGURE 4. Frequently affected quadrant

The age group with the highest medical addressability was that of adolescents aged between 13 and 16 years (10 cases), then addressability decreased.

The type of canine impaction is extremely important for the treatment method, as well as for the investigations required to establish the exact position. In the study performed, we obtained a proportion of 78% cases of palatal impaction and 22% cases of vestibular impaction (figure 5).

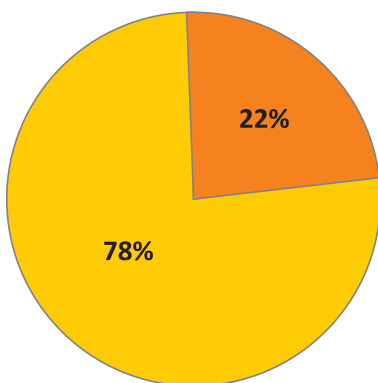


FIGURE 5. Type of canine impaction

The degree of impaction on OPT was established depending on the vertical height of the canine crown in relation to the lateral incisor, while the literature describes 4 degrees of impaction. The most frequent degree of impaction found in this study was 2nd degree (8 cases), followed by 3rd degree (6 cases), and 1st degree (4 cases); the 4th degree of impaction was not found in any case (figure 6).

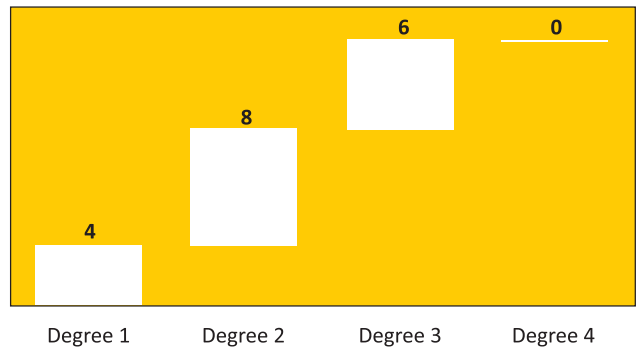


FIGURE 6. Degree of impaction

In bilateral impaction cases, the situation in which the lateral incisors were normal was predominant (2 cases), followed by the situation where the lateral incisors were small (1 case), while agenesis in both quadrants was not found.

Distribution depending on the space maintained in the arch through persistence of a deciduous canine shows a higher frequency of cases in which the deciduous canine persisted and implicitly maintained a space (53%) compared to cases where the deciduous canine was lost at the age of its exfoliation (47%) (figure 7).

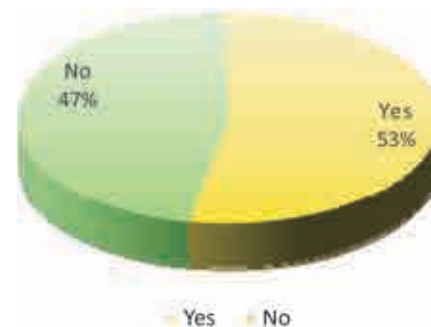

FIGURE 7. Persistence of deciduous canines

Maxillary canine impaction is an anomaly that can be found alone or may coexist with other anomalies. In this study, the most frequent anomaly associated with canine impaction was dentomaxillary disharmony with crowding in 35% of cases.

DISCUSSION

The frequency of canine impaction following the study was 8%, while the frequency of impaction in the general population is reported to be 2%. This considerable difference in results is generated by the fact that the examined patients were patients

who came to the clinic because of the presence of a dental anomaly, while in the general population there is a significant proportion of persons without dental anomalies.

Regarding the sex distribution of the number of cases, the result is contrary to those of the literature, where the female sex is reported to be more frequently affected.

The maxillary arch proved to be more frequently affected, the data obtained being in accordance with those of the literature [11]. The maxillary arch was affected in a proportion of 94% of the cases, while the mandibular arch was affected in 6% of the cases. The data obtained are explained by the different order of eruption of maxillary canines compared to mandibular canines.

The literature does not provide any data presenting a more frequent involvement of either the right or the left maxillary quadrant.

The high addressability during adolescence was due to functional and physiognomic impairment because of the absence of a permanent canine, but what made these patients perceive the absence of the permanent canine was the space present in the arch, even reduced. Patients were seldom aware of the persistence of a deciduous canine in the arch and came to the clinic for completely different reasons.

The data obtained regarding the type of impaction are in agreement with the literature data, which report a frequency of 85% cases of palatal impaction and 15% cases of vestibular impaction [11]. Permanent maxillary canine impaction is 20 times more frequent than mandibular canine impaction, and the female sex is 2 times more frequently affected than the male sex [11].

In the case of impacted teeth, using the CBCT scanning method enhances the ability to accurately locate the impacted canines, to evaluate proximity to adjacent teeth and other anatomical structures, to determine the size of the dental follicle, to detect the presence of a pathology, to estimate the space conditions, adjacent tooth resorption, to plan surgical access and to define the optimal direction for extruding teeth in the oral cavity [12-16].

In some cases of canine impaction, a distal inclination of the lateral incisor crown occurs, which leads to the appearance of a space in the incisor area [17-18].

Many studies have demonstrated a positive correlation between canine angulation and maxillary incisor inclination: the more mesial the inclination of the impacted canine, the more vestibularly (labially) inclined is the incisor crown [19].

Providing a space for the impacted canine will lead to further protrusion of the incisors, more so in cases of bilateral impaction than unilateral impaction [20].

Impaction of the maxillary canines is the most frequent eruption pathology after the mandibular and maxillary wisdom molars and accounts for about 2% of the general population. Sarcedoti and Bacceti found a 3 times higher prevalence of canine impaction in hypodivergent patients compared to patients with a normodivergent growth pattern, and thus demonstrated an association between the growth pattern and canine impaction [21-22].

Basdra et al. reported that class II/2 anomaly was associated with anomalies such as upper lateral incisor agenesis in association with canine impaction [23].

Other authors observed a correlation between maxillary retrognathia and canine-premolar transposition [24].

Oliver et al. (1989) found that 31 Caucasian patients had small lateral incisors on the side of canine impaction [25].

CONCLUSIONS

Canine impaction was found in 8% of all dentomaxillary anomalies of the patients included in the study. with a 1.25 higher frequency in men. In the great majority of the cases, impaction was located in the maxillary arch. the most frequent location was palatal, 78%. Unilateral impaction is 5 times more frequent than bilateral impaction. The highest addressability of the patients was in the 13-16 years age group. The most frequent degree of impaction is 2nd degree; the least frequent degree is 4th degree, which was not found in our study. Unaffected lateral incisors were found in a large number of patients, although small incisors and even agenesis were also detected. Persistence of a deciduous canine was found in half of the cases.

Conflict of interest: none declared
Financial support: none declared

REFERENCES

1. Ionescu E. Anomaliile dentare. Editura Cartea Universitară: București, 2005.
2. Boboc Gh. Aparatul dentomaxilar. Formare și dezvoltare. Editura Medicală: București, 1995.
3. Cocârlă E. Stomatologie Pediatrică. Editura Medicală Universitară „Iuliu Hațieganu”: Cluj-Napoca, 2000.
4. Cocârlă E. Ortodonție. Tipografia UMF „Iuliu Hațieganu”: Cluj Napoca, 1995.
5. Anic-Milosevic S, Varga S, Mestrovic S, Lapter-Varga M, Slaj M. Dental and occlusal features in patients with palatally displaced maxillary canines. *Eur J Orthod* 2009;31:367-73.
6. Al-Nimri K, Gharaibeh T. Space conditions and dental and occlusal features in patients with palatally impacted maxillary canines: An aetiological study. *Eur J Orthod* 2005;27:461-5.
7. Barwart O, Schamberger D, Richter M, Ulmer H. The functional evaluation of orthodontically aligned impacted canines. *Fortschr Kieferorthop* 1994;55:104-10.
8. Semb G, Schwartz O. The impacted tooth in patients with alveolar cleft. In: Andreason JO(Editor): Textbook and Colour. Atlas of Tooth Impactions. Munksgaard, Copenhagen 1997; 331-38.
9. Jacoby H. Etiology of maxillary canine impactions. *American Journal of Orthodontics* 1983;83:125-32.
10. Mesaroș M, Muntean A. Medicină dentară pediatrică. Editura Medicală Universitară „Iuliu Hațieganu”: Cluj-Napoca, 2012.
11. Varghese GK. A practical guide to the Management of Impacted Teeth. *Jaypee Brothers Medical Pub*; 2010.
12. Lai CS, Bornstein MM, Mock L, Heuberger BM, Dietrich T, Katsaros C. Impacted maxillary canines and root resorptions of neighbouring teeth: A radiographic analysis using cone-beam computed tomography. *Eur J Orthod* 2013;35:529-38.
13. Oberoi S, Knueppel S. Three-dimensional assessment of impacted canines and root resorption using cone beam computed tomography. *Oral Surg Oral Med Oral Pathol Oral Radiol* 2012;113:260-7.
14. Alqerban A, Jacobs R, Fieuws S, Willems G. Comparison of two cone beam computed tomographic systems versus panoramic imaging for localization of impacted maxillary canines and detection of root resorption. *Eur J Orthod* 2011;33:93-102.
15. Alqerban A, Jacobs R, Lambrechts P, Loozen G, Willems G. Root resorption of the maxillary lateral incisor caused by impacted canine: a literature review. *Clin Oral Investig* 2009;13:247-55.
16. Kapila S, Nervina JM. 3D Image-aided diagnosis and treatment of impacted and transposed teeth. In: Kapila S, ed. Cone beam computed tomography in orthodontics: indications, insights and innovations. Hoboken, NJ: Wiley-Blackwell; 2014; 349-81.
17. Kanavakis G, Curran KM, Wiseman KC, Barone NP, Finkelman MD, Srinivasan S, et al. Evaluation of crown-root angulation of lateral incisors adjacent to palatally impacted canines. *Prog Orthod* 2015; 16:4.
18. D'Oleo-Aracena MF, Arriola-Guillen LE, Rodriguez-Cardenas YA, Ruiz-Mora GA. Skeletal and dento-alveolar bilateral dimensions in unilateral palatally impacted canine using cone beam computed tomography. *Prog Orthod* 2017;18:7.
19. Baratieri C, Canongia AC, Bolognese AM. Relationship between maxillary canine intra-alveolar position and maxillary incisor angulation: A cone beam computed tomography study. *Braz Dent J* 2011; 22:146-50.
20. Kim Y, Park JU, Kook YA. Alveolar bone loss around incisors in surgical skeletal Class III patients. *Angle Orthod* 2009;79:676-82.
21. Ericson S, Kuroi J. Early treatment of palatally erupting maxillary canines by extraction of the primary canines. *Eur J Orthod*. 1988; 10:283-95.
22. Boyd RL. Clinical assessment of injuries in orthodontic movement of impacted teeth I. Methods of attachment. *Am J Orthod* 1982;82:478-486.
23. Jain S, Prakash AT, Agrawal M. Dento-skeletal characteristics of subjects with impacted mandibular canine(s). *J Indian Orthod Soc* 2015; 49:19-24.
24. Sarcedoti R, Bacceti T. Dentoskeletal features associated with unilateral or bilateral palatal displacement of maxillary canines. *Angle Orthod* 2004;74:725-732.
25. Oliver RG, Mannion JE, Robinson JM. Morphology of the maxillary lateral incisor in cases of unilateral impaction of the maxillary canine. *Br J Orthod*. 1989 Feb;16(1):9-16.