Ref: Ro J Stomatol. 2021;67(4)
DOI: 10.37897/RJS.2021.4.3

Analysis of fetal palate as a tool in prenatal ultrasound examination

Roxana Elena Bohiltea[1,2], Teodor Salmen[3,4], Octavian Munteanu[5,6], Costin Pariza[1], Ioanina Parlatescu[7], Vlad Dima[2], Emilia Maria Vladareanu[8], Valentin Varlas[1,2]

[1]Department of Obstetrics and Gynecology, "Carol Davila" University of Medicine and Pharmacy, Bucharest, Romania
[2]Filantropia Clinical Hospital, Bucharest, Romania
[3]Doctoral School, "Carol Davila" University of Medicine and Pharmacy, Bucharest, Romania
[4]"N.C. Paulescu" National Institute of Diabetes, Nutrition and Metabolic Disorders, Bucharest, Romania
[5]Department of Anatomy, "Carol Davila" University of Medicine and Pharmacy, Bucharest, Romania
[6]University Emergency Hospital Bucharest, Romania
[7]Department of Oral Pathology, Faculty of Dental Medicine, "Carol Davila" University of Medicine and Pharmacy, Bucharest, Romania
[8]Faculty of Medicine, "Carol Davila" University of Medicine and Pharmacy, Bucharest, Romania

ABSTRACT

Prenatal ultrasound examination should take place between 18 and 20 week of gestation and is important for early detection of fetal anomalies such as the facial malformations. One important anatomic element is the palate that raises echographic technical difficulties such as the shadowing by facial bones and, especially, by the superior alveolar ridge, the fetal prone position and its localisation, respectively, profoundly, inside of fetal head or anatomic obstacles such as the fetal tongue, so new echographic examination techniques are being under evaluation. The prenatal detection rate of fetal cleft palate remains low, so various methods of examination are being proposed. The ultrasound assessment of the fetal face is made by 2D ultrasound, technique completed by 3D ultrasound, which includes the evaluation in both axial and coronal planes, with the uvula being analysed in two types of section, transversal and sagittal. In the latter to epiglottis is a landmark that confirms the identification of the uvula and a normal uvula has a typical and resembling echographic pattern to the equal sign. Eventough, prenatal diagnosis of soft palate cleft is a real challenge, with low detection rate due to difficulty of its visualization during routine examination, and even if suspected, diagnostic accuracy is low.

Keywords: 2D ultrasound, 3D ultrasound, equal sign, cleft, soft palate, prenatal ultrasound examination

INTRODUCTION

Prenatal ultrasound examination of the foetal face is important for early detection of fetal anomalies such as the facial malformations (1). The optimal timing, in case of a single examination, is between 18 and 20 weeks of gestation and, in case, there are two examination available, the first should take place at 11 to 14 weeks of gestation, for evaluation of the nuchal translucency, the pregnancy dating and the early anatomic survey, and the second one between 18 and 20 weeks of gestation (2).

One particular element of the prenatal assessment is represented by the normal soft palate that raises echographic technical difficulties, so new echographic examination techniques are being under evaluation (3,4).

Corresponding author:
Teodor Salmen
E-mail: teodor.salmen@gmail.com

Article History:
Received: 19 November 2021
Accepted: 26 November 2021

The difficulties encountered include the shadowing by facial bones and, especially, by the superior alveolar ridge, the fetal prone position and its localisation, respectively, profoundly, inside of foetal head, especially for the posterior part of the palate. The soft tissues represent anatomic obstacles from the area, such as the fetal tongue, that makes even more difficult to delineate the palate from the other structures (1). The resulted prenatal detection rate of fetal cleft palate remains low, especially when it is an isolated defect, ranging between 1.4% if is alone, to 22%, if associated with cleft lip (4). The difficulty of a comprehensive complete and correct analysis of the fetal palate, has led to the proposal of various methods of examination, respectively the 2-dimensional (2D) and the 3-dimensional (3D) ultrasound examination (3,4,5).

We focus in our presentation especially on the assessment of the normal fetal soft palate by 2D routine ultrasound examination and we discuss the marker "equal sign" in the diagnosis of isolated cleft palate.

THE DEVELOPMENT OF FOETAL PALATE

The foetal palate forms between 5 to 12 weeks of gestation. Early, in the 6th week, the medial nasal prominences merge to form the median palatine process or the primary palate, the premaxillary part of the maxilla (6). The secondary palate develops early in the 6th week from the lateral palatine processes or the palatal shelves. They are 2 mesenchymal projections that extend from the internal aspects of the maxillary prominences. They elongate and ascent to a horizontal position, superior to the tongue at the 7th to 8th week, fusing with the nasal septum and the posterior part of the primary palate (6,7). The primary and secondary palates continue to the ossification process. The posterior of the lateral palatal processes extends beyond the nasal septum, forming the soft palate and uvula and does not become ossified (6,7).

Facial clefts can be unilateral, bilateral or affect the midline; anterior they involve the lip within the primary palate and posterior involve the secondary palate with or without involvement of the lip and the primary palate, or, sometimes, only the uvula is involved (8). A quarter of the facial clefts involve the lip, one half both the lip and the palate and a quarter only the palate, so the assessment of the foetal lip or palate is not complete without the examination of both; the examination of the palate extends from the premaxillary to the tip of uvula (9).

The assessment of the fetal face is made by 2D ultrasound (Figure 1), but nowadays this technique is completed by 3D ultrasound (Figure 2) and includes the evaluation in both axial and coronal planes, which can be best obtained in 68-95% of foetuses during the mid-trimester ultrasound screening visit (10,11).

The uvula is analysed in two types of section, respectively a transversal and a sagittal section – that passes through the fetal neck and the pharyngeal space and which has epiglottis as a landmark that confirms the identification of the uvula; a normal uvula has a typical and resembling echographic pattern to the equal sign – a hypoechoic space between two hyperechoic lines (12) (Figure 3). The tongue (Figure 4) and the alveolar ridge (Figure 5) normal aspect are important to be analysed as a complete assessment of the palate.

Wilhelm and Borgers reported in 2010 that the equal sign was present in 90.7% of the cases, while the soft palate was visualized in median section in 85.3% of cases; moreover, visualization of either the uvula or the soft palate was successful in 98.4% of the cases (12). So, while in a high percentage of cases, the structures of the soft palate are visualized successfully with 2D ultrasound and, moreover, if

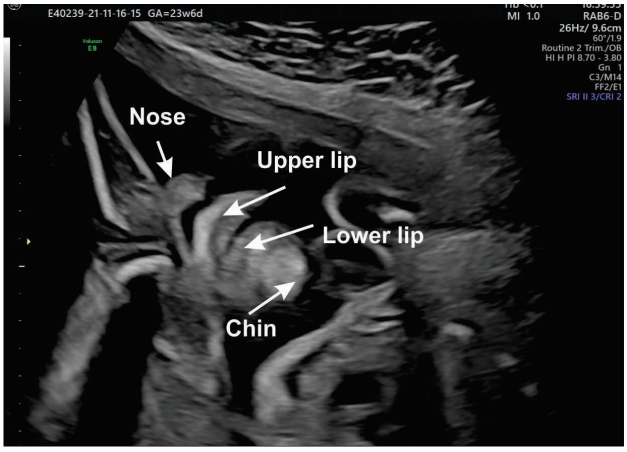

FIGURE 1. 2D ultrasound imaging in a fetus of 23-24 weeks of gestation. Note the normal aspect of the inferior compartment of the face

FIGURE 2. 3D ultrasound reconstruction of the face in a fetus of 27-28 weeks of gestation with a normal aspect of the face

FIGURE 3. 2D echographic aspect of a foetus of 27 weeks of gestation. Note the normal aspect of the uvula – the equal sign

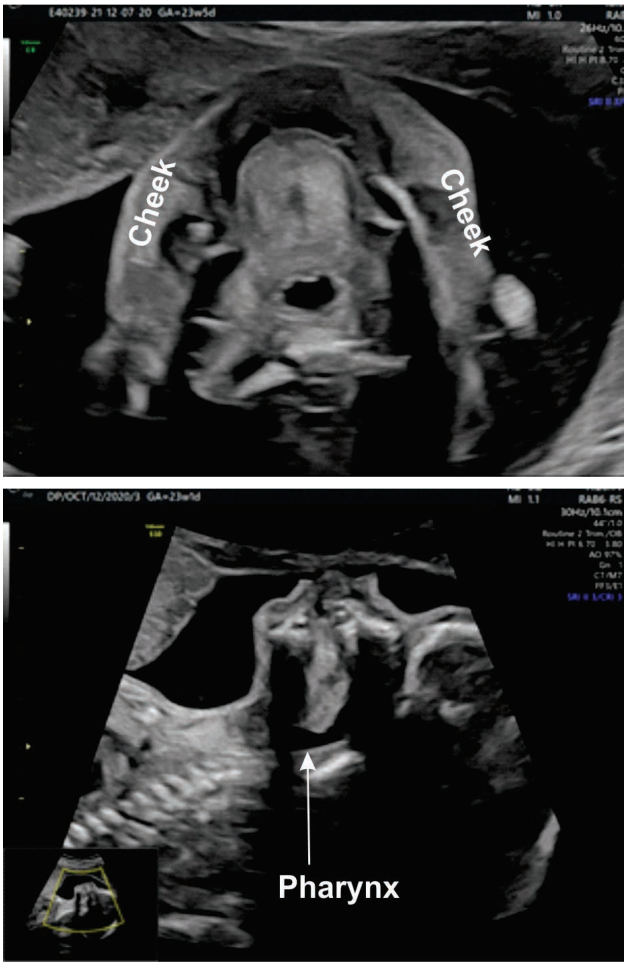

FIGURE 4. 2D echographic aspect of a foetus of 23-24 weeks of gestation. Note the normal aspect of the tongue in transversal plane (up) and sagittal plane (down)

associated with identification of the equal sign (Figure 1), that confirms an intact palate, the routine examination manages to rule out a cleft palate; and, on the other hand, the sign absence necessitate a prompt

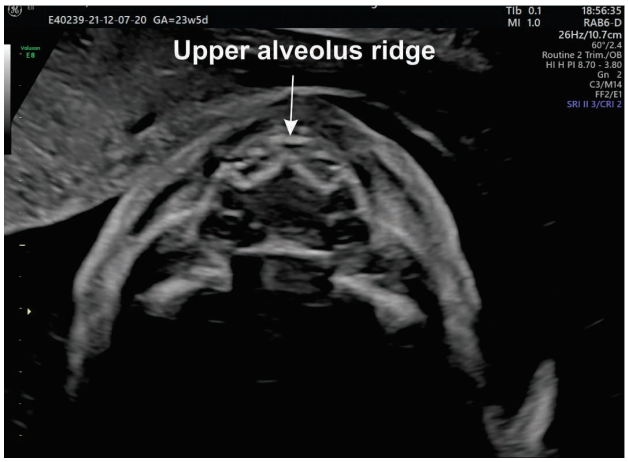

FIGURE 5. 2D echographic aspect in a fetus of 23-24 weeks of gestation. Note the normal aspect of the maxillary arch with dental alveoli in transverse section

examination of the soft palate in a median sagittal section, in order to rule out a cleft palate (12).

Prenatal diagnosis of soft palate cleft is a real challenge. The low detection rate is due to difficulty of its visualization during routine examination, and even if suspected, diagnostic accuracy is low (13).

Because of the dome – shaped structure of the palate and the associated difficulties in the 2D evaluation, a new approach is nowadays represented by the 3D examination of the palate, witch also have clear limitations regarding the assessment of the soft palate. Taking into account that there is no clear description of a cleft palate visualized using 3D ultrasonography, new different techniques are necessary to be developed in the field, complementary to the equal sign (14,15).

All cleft palates begin at the uvula and then extend a variable distance through the soft palate in the anterior direction, so the visualization of a normal uvula should be sufficient to rule out a cleft palate. 3D methods is not suitable for the routine detection of isolated cleft palate for different reasons: in screening programs usually is used 2D ultrasound, 3D visualization requires adequate ultrasound technical standard that are not always available and the acquisitions of excellent volumes limiting its use (12).

CONCLUSIONS

In summary, a normal uvula as “an equal sign” in a large majority of fetuses, even in suboptimal ultrasound condition, can be obtained and help to rule out the cleft palate in situation of isolated cleft palate. Even if the assessment of cleft palate is difficult in 2D ultrasound examination, the novel approach by 3D ultrasound examination bring some advantages, but is not sufficient as an alternative.

REFERENCES

1. Meizner I, Katz M, Bar-Ziv J, Insler V. Prenatal sonographic detection of fetal facial malformations. *Isr J Med Sci.* 1987 Aug;23(8):881-5.
2. Committee on Practice Bulletins – Obstetrics and the American Institute of Ultrasound in Medicine. Practice Bulletin No. 175: Ultrasound in Pregnancy. Obstet Gynecol. 2016 Dec;128(6):e241-e256.
3. Frisova V, Cojocaru L, Turan S. A new two-dimensional sonographic approach to the assessment of the fetal hard and soft palates. *J Clin Ultrasound.* 2021 Jan;49(1):8-11.
4. Gindes L, Weissmann-Brenner A, Zajicek M, Weisz B, Shrim A, et al. Three-dimensional ultrasound demonstration of the fetal palate in high-risk patients: the accuracy of prenatal visualization. *Prenat Diagn.* 2013 May;33(5):436-41.
5. Jones MC. Prenatal diagnosis of cleft lip and palate: detection rates, accuracy of ultrasonography, associated anomalies, and strategies for counseling. *Cleft Palate Craniofac J.* 2002 Mar;39(2):169-73.
6. Danescu A, Mattson M, Dool C, Diewert VM, Richman JM. Analysis of human soft palate morphogenesis supports regional regulation of palatal fusion. *J Anat.* 2015 Oct;227(4):474-86.
7. Bush JO, Jiang R. Palatogenesis: morphogenetic and molecular mechanisms of secondary palate development. *Development.* 2012 Jan;139(2):231-43.
8. Abramyan J, Richman JM. Recent insights into the morphological diversity in the amniote primary and secondary palates. *Dev Dyn.* 2015 Dec;244(12):1457-68.
9. Offerdal K, Blaas HG, Eik-Nes SH. Prenatal detection of trisomy 21 by second-trimester ultrasound examination and maternal age in a non-selected population of 49 314 births in Norway. *Ultrasound Obstet Gynecol.* 2008 Sep;32(4):493-500.
10. Pretorius DH, Nelson TR. Three-dimensional ultrasound. *Ultrasound Obstet Gynecol.* 1995 Apr;5(4):219-21.
11. Pilu G, Reece EA, Romero R, Bovicelli L, Hobbins JC. Prenatal diagnosis of craniofacial malformations with ultrasonography. *Am J Obstet Gynecol.* 1986 Jul;155(1):45-50.
12. Wilhelm L, Borgers H. The ‚equals sign’: a novel marker in the diagnosis of fetal isolated cleft palate. *Ultrasound Obstet Gynecol.* 2010 Oct;36(4):439-44.
13. Clementi M, Tenconi R, Bianchi F, Stoll C. Evaluation of prenatal diagnosis of cleft lip with or without cleft palate and cleft palate by ultrasound: experience from 20 European registries. EUROSCAN study group. *Prenat Diagn.* 2000 Nov;20(11):870-5.
14. Pilu G, Segata M. A novel technique for visualization of the normal and cleft fetal secondary palate: angled insonation and three-dimensional ultrasound. *Ultrasound Obstet Gynecol.* 2007 Feb;29(2):166-9.
15. Faure JM, Captier G, Bäumler M, Boulot P. Sonographic assessment of normal fetal palate using three-dimensional imaging: a new technique. *Ultrasound Obstet Gynecol.* 2007 Feb;29(2):159-65.

Conflict of interest: none declared
Financial support: none declared