

Orthodontic movement of teeth with horizontal root fracture: a case report

Nader Giacaman¹, Mohammed R. Jaradat²

¹Department of Dental Sciences, Arab American University of Palestine (AAUP), Ramallah, Palestine

²Department of Orthodontics and Pedodontics, Arab American University of Palestine

ABSTRACT

Horizontal root fractures involve injuries to the dentin, pulp, cementum, and periodontal ligament. Although this type of injury is relatively rare, comprising only 0.5–7% of all trauma cases in the permanent dentition, orthodontists should possess adequate knowledge to manage cases involving this type of traumatic dental injury. This case study reports the successful outcome of orthodontic management for a patient with Class II Division 2 malocclusion complicated by crowding and a horizontal root fracture of an upper permanent central incisor. The root-fractured tooth was successfully moved, allowing the patient to retain his natural tooth and providing a viable alternative to extraction and prosthetic replacement for teeth with horizontal root fractures in patients requiring comprehensive orthodontic treatment.

Keywords: horizontal root fractures, pulp vitality, panoramic x-ray, orthodontic management

INTRODUCTION

Management of traumatized teeth requires a significant amount of clinical knowledge and experience. Various forms of tooth injuries exist, including concussion, subluxation, luxation injuries, crown fractures, and root fractures. An orthodontist should be well-versed in managing these conditions, as more than 10% of patients presenting for orthodontic treatment show evidence of trauma. [1]. Horizontal root fractures represent a combination of injuries to the pulp, dentin, cementum, and periodontal ligament. Although they are not common, they account for 0.5-7% of all trauma cases involving permanent dentition and are more frequently observed among 11-20-year-old males, primarily in the maxillary anterior region, with the middle third of the root being the most affected, followed by the apical and coronal thirds [2,3]. Moving root-fractured teeth horizontally via orthodontic appliances is possible, but certain precautions must be taken. This paper elucidates the orthodontic movement of a tooth with a previous horizontal root fracture.

CASE REPORT

Diagnosis and etiology

A 16-year-old male patient was referred to the orthodontic clinic for malocclusion management. The patient was medically fit and healthy. His dental history revealed trauma to his anterior teeth five years prior. He complained of irregular front teeth. Clinical and radiographic examinations were performed, revealing a symmetric face, an average smile line, and reduced lower anterior facial height.

The intraoral examination showed a Class II Division 2 incisor relationship on a skeletal Class I base (ANB = 3.7 degrees/ Figure 2) complicated by crowding in both dental arches and an impacted lower right second premolar (Figure 1).

The radiographic examination confirmed a horizontal root fracture in the middle third of the upper right central incisor (Figure 2). All maxillary anterior teeth responded positively to electric pulp testing.

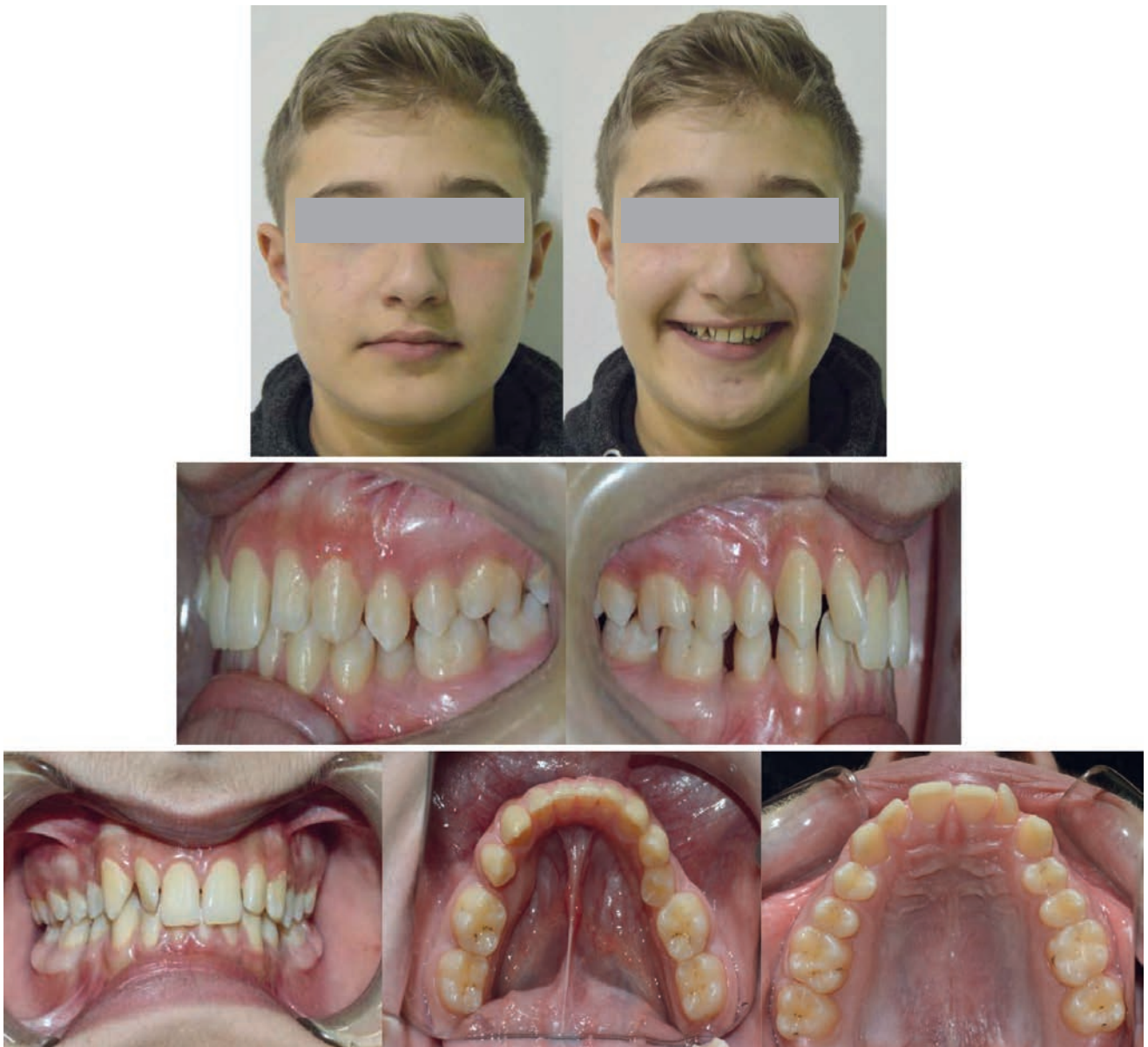


FIGURE 1. Pre-treatment extraoral and intraoral photographs (taken using Nikon digital SLR Camera D3200)

Treatment objectives

Following thorough clinical and radiographic examinations, the treatment objectives were to:

- A. Align the crowded teeth.
- B. Create enough space to align the impacted mandibular second premolar.
- C. Normalize the overbite.
- D. Achieve a class I incisor, canine, and molar relationship.
- E. Maintain the vitality of the root- fractured maxillary right central incisor by the end of orthodontic treatment.

Treatment alternatives

The patient was presented with two treatment options, both involving the use of a fixed orthodontic appliance:

- a) Fixed orthodontic treatment with the extraction of the maxillary right central incisor and

replacement with a dental implant and prosthesis.

- b) Fixed orthodontic appliance treatment with a non-extraction approach.

The patient chose the second option. A written informed consent was obtained from the patient after explaining the risk of root fragments separation and loss of pulp vitality at the end of the orthodontic treatment.

Treatment progress

Fixed orthodontic appliance was bonded onto both arches using a 0.022 slot MBT prescription. The treatment began with the placement of 0.014 NiTi arch wires to initiate tooth alignment, followed by sequential arch wires (0.016 NiTi, 0.016 × 0.022 NiTi, 0.017 × 0.025 NiTi, and 0.019 × 0.025 NiTi) over six months to complete the alignment.

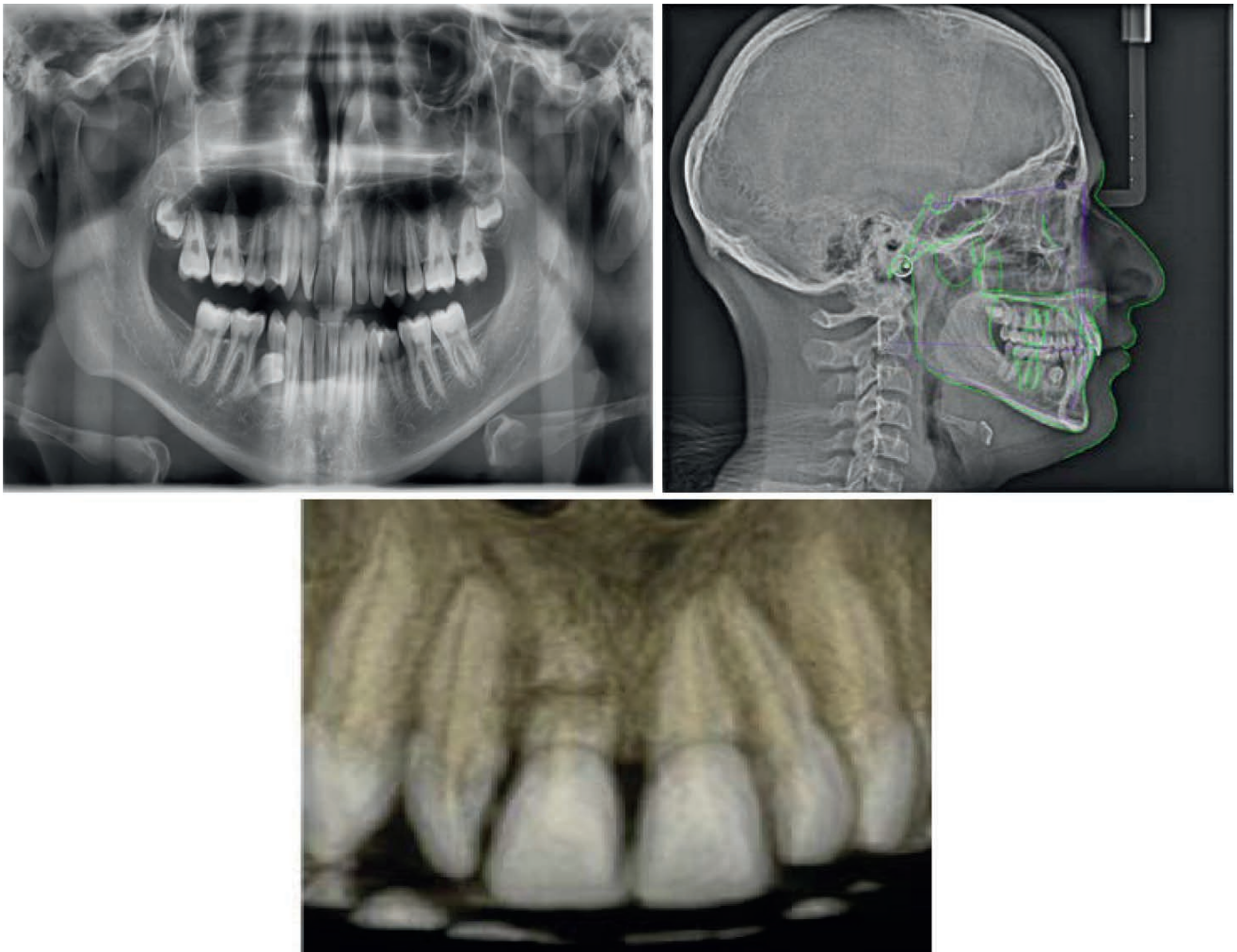


FIGURE 2. Pre-treatment panoramic, lateral cephalometric & CBCT X-rays

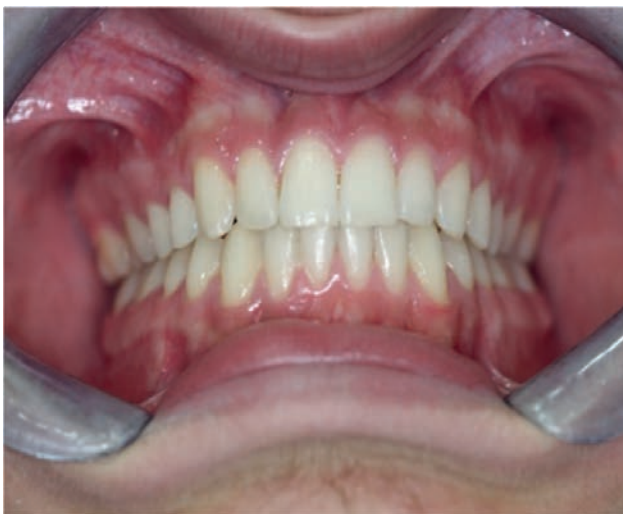

FIGURE 3. Post-operative frontal view for the occlusion (taken using Nikon digital SLR Camera D3200)

Subsequently, 0.019 × 0.025 stainless steel orthodontic arch wires were placed in both arches as working arch wires. In the lower arch, an active NiTi open coil spring was placed between the lower right first premolar and first permanent molar to create space for the impacted lower right second

premolar, which erupted spontaneously without any surgical intervention after sufficient space was created, allowing realignment of the lower teeth. After that, a 0.017 × 0.025 NiTi arch wire with a reverse curve of Spee was placed in the lower arch to level the curve of Spee through middle teeth extrusion, as well as intrusion and proclination of the lower incisors. The leveling stage lasted four months. Following overbite correction, 0.019 × 0.025 stainless steel arch wires (with a reverse curve of Spee in the lower arch) were placed in both arches as working arch wires. Subsequently, the patient was provided with Class II intermaxillary elastics to achieve Class I relationships for the incisors, canines, and molars. Lastly, a 0.021 × 0.025 TMA arch wire was placed as the finishing arch wire. Overall, the treatment duration was 20 months.

Treatment results

At the end of the 20 months of active orthodontic treatment, both the maxillary and mandibular teeth—including the impacted mandibular second premolar—were successfully aligned. The incisors, canines, and molars achieved a Class I relationship

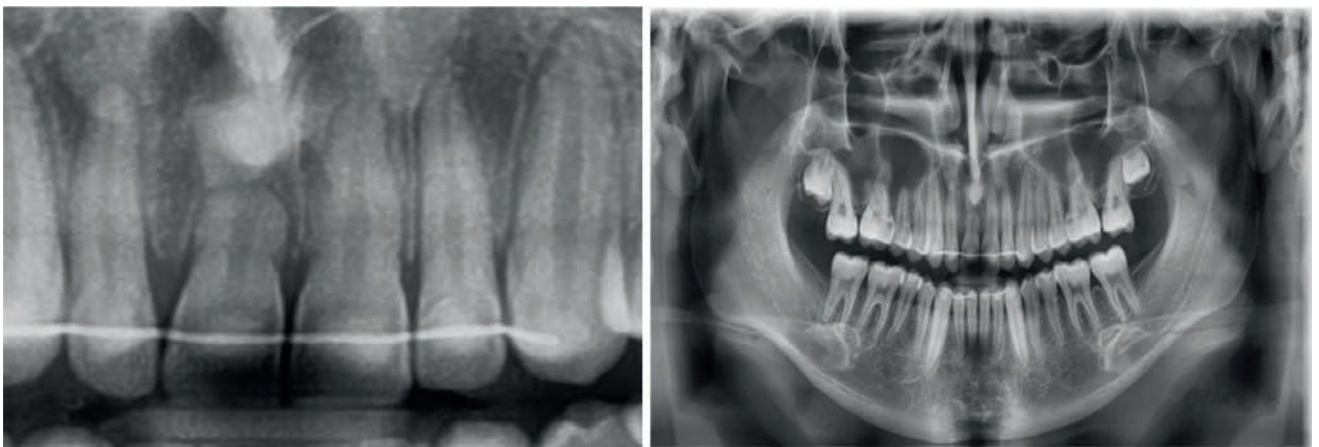


FIGURE 4. Post-operative x-rays

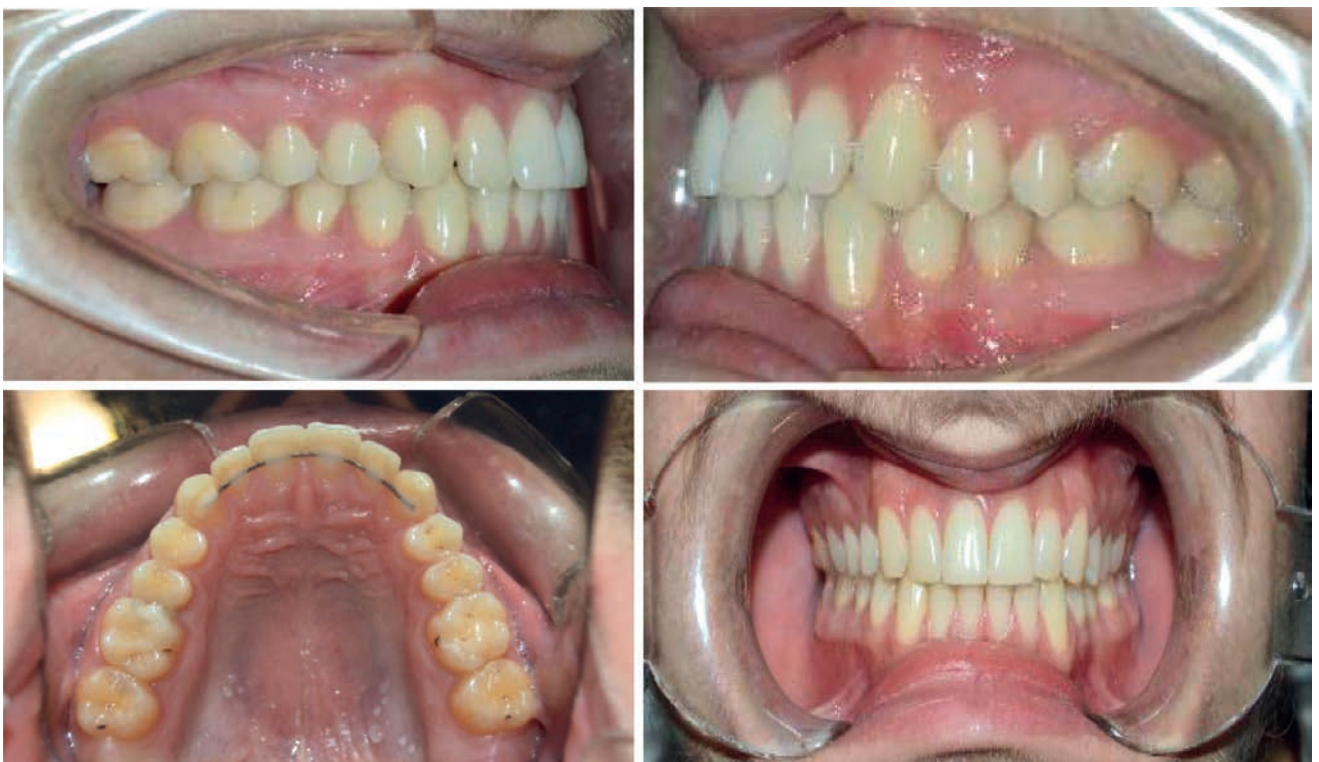

FIGURE 5. Follow-up extraoral and intraoral photographs (taken using Nikon digital SLR Camera D3200)

with an average overbite (Figure 3). The post-operative panoramic X-ray revealed the separation of the apical and coronal root segments of the maxillary right central incisor (Figure 4). Additionally, the vitality test using ethyl chloride confirmed the presence of a vital pulp. Table 1 illustrates the flowchart for the orthodontic treatment.

DISCUSSION

According to the management guidelines for traumatic dental injuries by the International Association of Dental Traumatology, the treatment for teeth with transverse root fractures includes repositioning and stabilizing the coronal fragment in its anatomically correct position. This step should be implemented as soon as possible to optimize the healing of the periodontal ligament and neurovascular supply, while also preserving both aesthetic and functional integrity [4].

Cvek et al. 2001 found that root development and repositioning of dislocated fragments were highly predictive of the frequency and type of healing, as compared to other factors such as splinting and its duration. Specifically, teeth with no or minimal loosening of the coronal fragment may not require splinting [5]. In this case, there was no prior intervention, including splinting, for the fractured tooth. Consistent with the literature, up to 80% of transverse root fractures can heal with or without initial treatment; however, the extent of healing can vary widely. Healing outcomes may range from granulation tissue (the worst prognosis) to connective tissue formation, bone formation, and ultimately hard tissue formation in the best scenarios [6].

There is a lack of published reports regarding the orthodontic movement of root-fractured teeth. However, guidelines consistently recommend an observation period of at least two years following the initial orthodontic tooth movement [7]. Our patient was exposed to trauma five years before the orthodontic consultation. Thus, the tooth was considered to have moved orthodontically after a sufficient observation period.

For teeth healed with hard tissue formation, orthodontic movement can be achieved without separating the apical and coronal fragments, provided they remain consolidated. Conversely, root-fractured teeth healed with connective tissue formation carry a higher risk of separation of the apical and coronal fragments when orthodontic forces are applied [2]. Therefore, the patients must be informed about this possibility before the start of orthodontic treatment, especially if the fracture occurs in the middle-third region as it may result in a short tooth with reduced periodontal support at the end of orthodontic treatment. In our case, a specialist endodontist was consulted. The patient was informed

TABLE 1. Flowchart for the orthodontic treatment

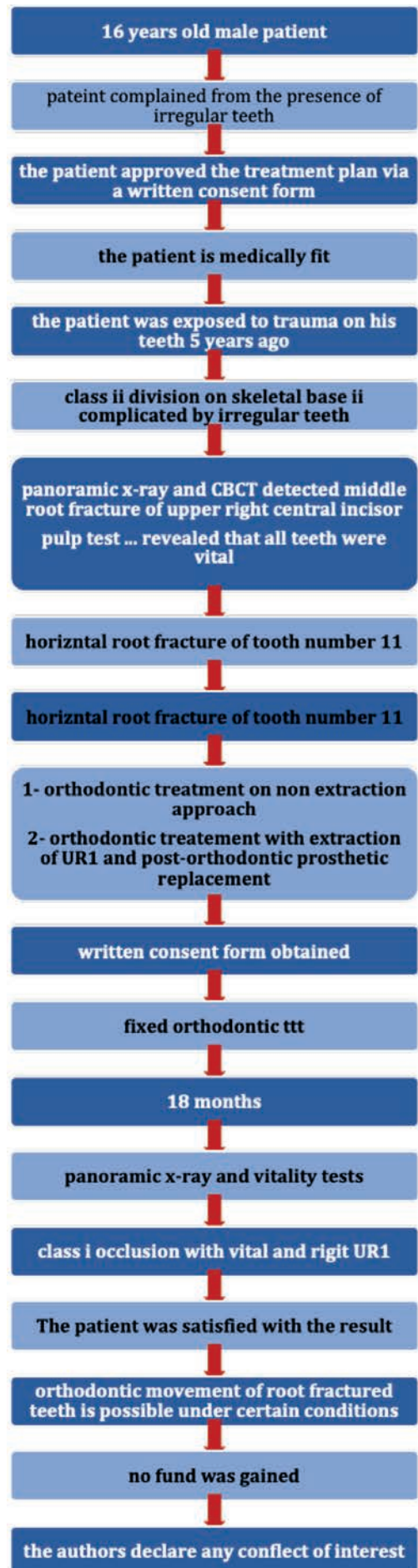

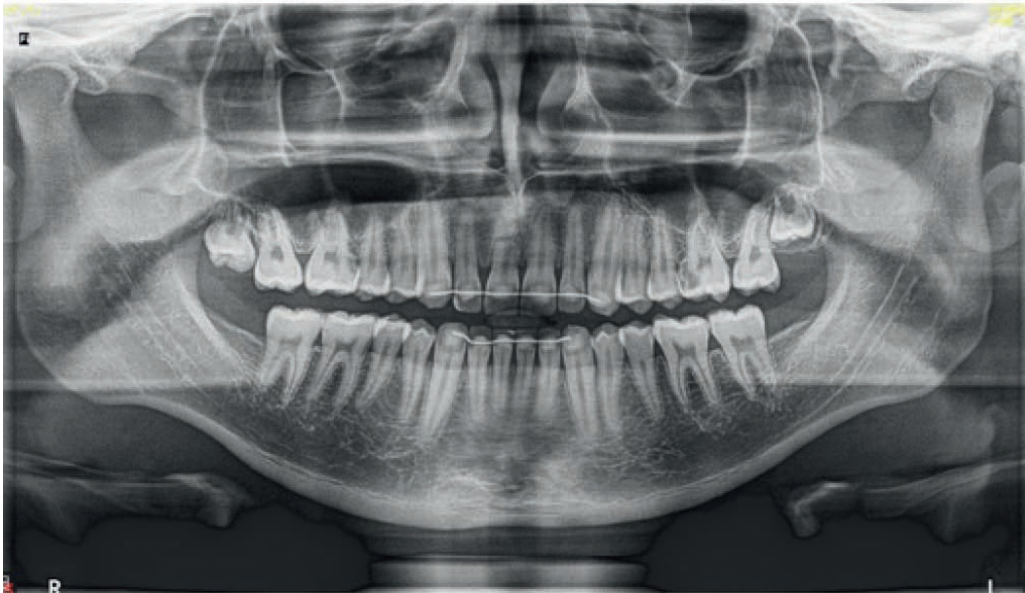


FIGURE 6. Follow up panoramic x-ray

about the risk of root segment separation at the end of active treatment. The patient understood and accepted the risk, opting to retain his injured tooth rather than undergo extraction and replacement with a dental implant and prosthesis. At the end of the active treatment, the clinical and radiographic examinations indicated that the tooth remained rigid and vital, despite evidence of root segment separation.

At each stage of orthodontic treatment, the risk of root injury was minimized. During the alignment phase, only light levels of orthodontic force were applied. Follow-up visits were scheduled at six-week intervals to minimize any potential harm to the roots, particularly the injured upper right central incisor. During the management of deep bite in the leveling stage, a 0.017×0.025 NiTi arch wire with a reverse curve of Spee was placed in the lower arch instead of the upper arch to avoid applying intrusive forces on the upper incisors, particularly the upper right central incisor. This is important because traumatized maxillary incisors with severe periodontal injuries are more susceptible to pulp necrosis during orthodontic intrusion compared to non-traumatized teeth [8].

At the end of the active treatment, the appliance was debonded, and the patient was given two types of retainers in each arch; a bonded fixed retainer and a removable Essex retainer. Although teeth with horizontal root fractures have a greater potential for maintaining vital dental pulp compared to luxated teeth without fractures, pulp necrosis can still occur in 20% to 44% of cases. For teeth with retained vitality, the reason may be attributed to the force that occurs during the fracture being transmitted to the apical region of the tooth, resulting in re-

duced force and an increased likelihood of revascularization at the fracture site. Furthermore, it is believed that the fractured area provides an avenue of escape for fluid pressure from edema, therefore allowing collateral circulation from the periodontal ligament to assist in maintaining the vitality of the traumatized pulp [9]. In our case, the patient was followed up for 18 months and the subsequent clinical and radiographic examinations yielded satisfactory results (Figures 5 and 6).

CONCLUSION

Orthodontists must be well-versed in managing traumatized teeth, as over 10% of patients seeking orthodontic treatment present with some evidence of trauma. The orthodontic movement of a horizontally root-fractured tooth with healed connective tissue is feasible following an adequate observation period and the application of light forces. In this case, although the root segments were separated at the end of treatment, the tooth retained its vitality and rigidity, and the patient expressed satisfaction with the results.

Acknowledgment: The authors provided the equipment and materials used for the treatment of the patient without any external funding sources.

Patient consent: The patient provided written informed consent for publication of this case report, including clinical photographs and radiographic images, in accordance with ethical guidelines.

Conflict of interest: All the authors declare that they do not have any conflict of interest or any financial interest in this article.

REFERENCES

- Bauss O, Röhling J, Schwestka-Polly R. Prevalence of traumatic injuries to the permanent incisors in candidates for orthodontic treatment. *Dent Traumatol.* 2004;20(2):61-6. PMID: 15025687. <https://doi.org/10.1111/j.1600-4469.2004.00230.x>
1. Lo Giudice R, Lizio A, Cervino G, Fabiana N, Francesco P, Ausiello P, Cicciù M. The Horizontal Root Fractures. Diagnosis, Clinical Management and Three-Year Follow-Up. *Open Dent J.* 2018;12:687-95. <https://doi.org/10.2174/1745017901814010687>. PMID: 30369978; PMCID: PMC6182880.
 2. Gharechahi M. Horizontal root fracture accompanied by luxation of coronal fragment in a maxillary central incisor: a case report. *J Dent Res Dent Clin Dent Prospects.* 2013 Fall;7(4):244-7. <https://doi.org/10.5681/joddd.2013.039>. Epub 2013 Dec 18. PMID: 24578824; PMCID: PMC3935557.
 3. Bourguignon C, Cohenca N, Lauridsen E, Flores MT, O'Connell AC, Day PF, et al. International Association of Dental Traumatology guidelines for the management of traumatic dental injuries: 1. Fractures and luxations. *Dent Traumatol.* 2020;36(4):314-30.
 4. Cvek M, Andreasen JO, Borum MK. Healing of 208 intra-alveolar root fractures in patients aged 7-17 years. *Dent Traumatol.* 2001;17(2):53-62. <https://doi.org/10.1034/j.1600-9657.2001.017002053.x>. PMID: 11475947.
 5. Poi WR, Manfrin TM, Holland R, Sonoda CK. Repair characteristics of horizontal root fracture: a case report. *Dent Traumatol.* 2002;18(2):98-102. <https://doi.org/10.1034/j.1600-9657.2002.00071.x>. PMID: 12184220.
 6. Andreasen O, Andreasen FM, Andersson L. Textbook and color atlas of Traumatic injuries to the Teeth. 4th ed. England. Blackwell publishing Ltd;2007. p. 671
 7. Bauss O, Röhling J, Sadat-Khonsari R, Kiliaridis S. Influence of orthodontic intrusion on pulpal vitality of previously traumatized maxillary permanent incisors. *Am J Orthod Dentofacial Orthop.* 2008;134(1):12-7. <https://doi.org/10.1016/j.ajodo.2006.07.033>. PMID: 18617098.
 8. Erdemir A, Ungor M, Erdemir EO. Orthodontic movement of a horizontally fractured tooth: a case report. *Dent Traumatol.* 2005 Jun;21(3):160-4. <http://doi.org/10.1111/j.1600-9657.2005.00286.x>. PMID: 15876328.